



Caries Detection in Panoramic Dental X-ray Images Using Support Vector Machine

Muna Khalid Jasim, Khalid al- kaabneh

Computer Science Department, Amman Arab University, Amman, Jordan

ABSTRACT

Detection of tooth caries is very important through panoramic X-rays (extra oral), so that the dentist can develop a plan of treatment suitable for the patient, in addition to panoramic X-rays describe many of the dental diseases that affect a very large number of people around the world. In this paper, we propose the way image processing techniques will examine the panoramic X-ray image to detect dental caries using Histogram Equalization (HE) and Adaptive Histogram Equalization (AHE) to remove noise from an image and then cropping the region of interest (ROI). Then we will take the feature extracted from the images by the Histogram Oriented Gradient (HOG) and Scale Invariant Feature Transform (SIFT), which are the descriptor and detector used in this research, and finally the classifier Support Vector Machine (SVM) is used to detect teeth caries.

Key words: Panoramic Dental Images, Caries detection, Feature extraction, Histogram Oriented Gradient, Scale Invariant Feature Transform, Fusion HOG and SIFT

1. INTRODUCTION

X-ray plays a significant role in the diagnosis and detection of problems with teeth; describing the condition of teeth using X-ray is a source of basic data in the diagnosis process. X-ray imaging is the photographic record of the image generated by the transit of an X-ray source through an object. Without X-rays, the dentist cannot detect many diseases which affect the teeth, gums and jaws. X-rays help the dentist detect diseases at an early stage, which leads to the best treatment plan for the patient.

To obtain an effective diagnosis in the field of dentistry, the tools of the computer have been used in diagnosis, analysis and discovery of caries or any other disease that affects the teeth easily [1]. In this research, a panoramic X-ray image of the teeth will be taken, and digital image processing methods will be used to obtain the desired result. X-ray images of teeth are classified into two categories [2]:

Intra- oral radiographic.
Extra- oral radiographic.

Intra oral radiographic are divided into two types: Bitewing and Preipical, while extra- oral radiographic is panoramic. Bitewing X-ray image is used to show specifics of upper and lower teeth in a mouth region, while the Periapical X-ray image is used to examine teeth inside the mouth as requested by the dentist [3]. Extra-oral radiographic (panoramic) can obtain basic information to diagnose defects in dentistry [3][4].

Panoramic x- ray shows a wide vision of the jaws, teeth, sinuses, nose area, and jaw joints, these rays show many teeth problems such as infected teeth, bone abnormalities, sores, solid growth (tumors), infections, fractures and tooth decay [5].

There are several factors that affect the X-ray [6], which make it difficult to analyze the image and detect the disease, such as the differences between the teeth of different patients, and the fillings or repairs within the tooth. The image is of low quality due to certain conditions experienced by the image, such as (noise, low contrast, homogeneity in areas near the details to be interested, the space available due to tooth loss; all these challenges makes it difficult for the computer to analyze and diagnose teeth problems perfectly [3].

There are three kinds of tooth decay: the first type is enamel decay which is preceded by the formation of a microbial dental plaque; the second type is dentinal caries, which begin to spread naturally along with great numbers of dentinal tubules, and which are difficult to detect during the visual examination and require careful clinical examination using X-ray; the third type is the most severe, and involves inflammation of the pulp which corresponds to root caries or root surfaces [7].

After understanding the different types of X-rays and each of the caries, the next step in the process of image enhancement and quality is crucial, because it greatly helps to extract its properties [8].

Then Feature extraction is very significant process in most of the image processing applications, the extracted information is used to describe the objects features and structure, the final representation of the object features is a vector of real numbers. We tried to use the most efficient spatial descriptors such as a Histograms of Oriented Gradients (HOG), Scale-Invariant Feature Transform (SIFT) and fusion HOG and SIFT. Finally, the classifier support vector machine (SVM) is used to detect teeth caries or healthful depending on the results from HOG and SIFT.

Dental panoramic images are important resource during diagnosing and detecting tooth decay, therefore panorama images are taken into consideration in several dental diagnosing researches in literature review.

[10] proposed a method used in his paper has focused on the challenges faced by dentists in detecting tooth decay at an early stage through X-ray.

The dentist uses clinical examination to diagnose tooth decay by looking directly, but there are cases that are difficult to diagnose except through X-rays. The automated system would help the dentist to identify the caries in teeth by making use of X-ray [11] while the researcher [12] explained the main challenge during X-ray image processing is the detection of edges because it is the most important stage in the process of image processing, for detecting caries. Pointed out [7] that the very fine differences in the image of X-ray lead to the difficulty of interpretation and discovery of diseases that affect the teeth, which requires scientific methods to address the problems that occur in the image of X-ray. The process of segmentation teeth and detect the edges through the image of X-ray is of great importance in several areas, including: Estimate the age of teeth and this helps in determining the age of unidentified bodies [13]. X-ray images of the teeth were used to identify human identity by taking dental X-ray images and detect edges using Sobel algorithm [14].

[15] Discussed in this paper, a tooth decay detection system was introduced in the light of SVMs that were trained using the Practical Improvement of the Squadron (PSO). The proposed approach uses inter-pixel interconnection as input features. Experimental results have shown that the proposed method can detect tooth decay efficiently. [16] In his paper, a method was proposed to improve image using watersheds. A dentist can help to find caries easier. The decay diagnosis algorithm was built and tested based on the modified SVM kernel function. [17] Discuss the process of segmentation teeth using X-ray by the morphological method of dividing teeth, he suggests using a Histogram Oriented Gradients (HOGs) and image invariants to use as features for training classifiers SVM.

Background of Dental Panoramic X-Ray and Dental Caries

Dental panoramic X-ray is a type of X-ray that use a very small dose of ionizing radiation to capture the entire mouth in one image. This image taken by dentists' specialists in the field of dental imaging. This radiation is used in the planning of denture treatment, dental root examination, dental caries, dental wisdom and other problems affecting the mouth and teeth. The analysis of X-ray images remains a major challenge when dealing with extra-oral radiographs (panoramic X-ray), because these images are not only restricted to an isolated part of the teeth, as happens in the intra-oral images, in addition to the teeth, panoramic X-rays also show the temporomandibular regions (jaw joints with the skull) and details originated by the bones of the nasal and facial areas [2].

Dental Caries, also known as dental decay or tooth decay, is defined as a disease of the hard tissues of the teeth caused by the action of microorganisms found in plaque on fermentable

carbohydrates (principally sugars). Therefore, the detection of dental caries in initial stage is significant task [5].

1.2 Problem Formulation

Dental x-rays may appear on dental caries before they appear visible, special caries between teeth. Large dental caries is usually visible to the human eye, but smaller lesions are hard to detect. So, dentists use radiographs to get a correct diagnosis.

The research problem summarized below:

Lacks of researches in detect dental caries through panoramic X - ray images.

Difficulties obtaining of the edge's detection and a good segmentation of teeth, especially final teeth through the panoramic X-ray image.

Difficulties in detecting dental caries in panoramic X-ray images arise due to many reasons, such as: incorrect lighting, movement while taking a picture, and other factors.

1.3 Objectives and Benefits of Research

The quality of some X-rays images can suffer from lack of clarity, color imbalance, motion during capture, and other factors that produce an unclear image and make it difficult for the dentist to diagnose and detect decay.

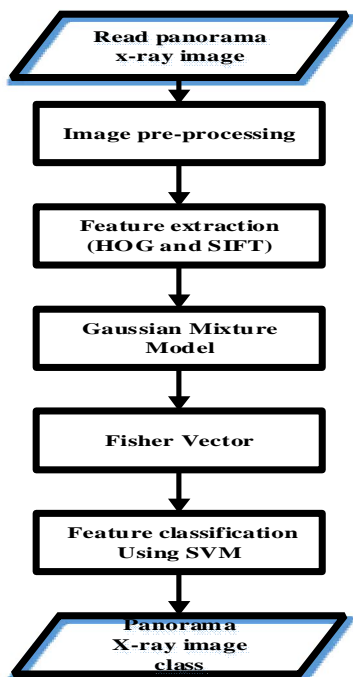
This research emphasizes the importance of using image processing tools and computer vision in the treatment of X-rays, obtaining a clear image through the panoramic X-ray without the need to repeat radiography and give the patient another dose of radiation, which is a major risk to human health [9].

The significance of this study could be summarized by the following points:

- The main objective of this research is to detect dental caries through Panoramic X-rays.
- A new method of detecting tooth decay has been added to the literature on caries detection through a panoramic X-ray image.
- This research may be the basis for other methods in detecting caries and it is possible to improve it.

2. THEORETICAL

In this research Error! Reference source not found. below shows the main steps of the proposed model for dental caries detection based on panoramic X-ray image. The proposed model includes several phases: at the beginning, pre-processing operations are needed to process the input image, these operations include: reducing image size, converting images to gray level and noise removal. Then Histogram Equalization and Adaptive Histogram Equalization are used to optimize the image and adjust the image color. The features are extracted using the HOG and SIFT detectors and descriptors. Then use Gaussian mixture model for clusters. Finally, Support Vector Machine is used for feature classification, which will distinguish healthy from decayed teeth.



Error! Reference source not found.: The propped model

3. METHODOLOGY

A. Preprocessing

The main steps of preprocessing can be summarized as follows:

- Reading the panoramic X-ray image.
 - Resizing the input image to a certain size for all used images.
 - Convert the image to gray scale level.
 - Apply Histogram Equalization (HE).
 - Improve contrast in image by using Adaptive Histogram Equalization (AHE).
- Crop the image to focus on the upper and lower jaw area, this represent the region of interest in our approach.

B. Features Extraction

Feature extraction is very important process in most of the image processing applications, the extracted information is used to describe the objects features and structure, the final representation of the object features is a vector of real numbers. There are different kinds of feature descriptors in the literature, in our case we are dealing with spatial feature therefore, we tried to use the most efficient spatial descriptors such as a Histograms of Oriented Gradients (HOG) and Scale-Invariant Feature Transform (SIFT).

Histograms of Oriented Gradients (HOG)

Is one of the well-known feature descriptors types, the histogram of gradient directions (oriented gradients) are used as descriptor. The pixels Gradients in vertical and horizontal directions of the image represent the first derivatives of image pixels intensities. The magnitude of gradient is large around edges and corners (pixels intensities are regions suddenly changed). Edges and corners contain a lot of information about object compared with other regions [18].

Scale-Invariant Feature Transform (SIFT)

Is one of most effective, robust and fast feature descriptor types. SIFT gives stable results even in images with different conditions such as illumination changes, resolution, geometric deformation, scale, rotation [19]. SIFT can be used to detect and describe features at the same time.

Gaussian mixture model

Is used to model the distribution of features extracted all the image. Probabilistic model-based clustering techniques have been widely used and have shown promising results in many applications, ranging from image segmentation, handwriting recognition, document clustering, topic modeling to information retrieval. Model-based clustering approaches attempt to optimize the fit between the observed data and some mathematical model using a probabilistic approach.

D. Fisher vector (FV)

Fisher vectors was originally suggesting in as a framework to build a special classifier from a generative model. It was later applied to image classification, by modeling the image as a bag of local features sampled from an image [20]. The FV is an image representation obtained by collect local image features. It is frequently used as an image descriptor in classification.

E. Features Classification

After features extraction, classification process is needed to classify the extracted features into two kinds of classes healthy and decayed teeth, therefore support vector machine is used in this phase. Classification is a technique to identify the class label of the features, usually the features and the labels for these features are provided to the classifier, this way of classification is called supervised learning. There are two stages during the classification process: the learning phase, where the training data is analyzed, and rules are generated, the second stage is the classification, where test data is classified into classes according to the generated rules [21]. Support Vector Machine are a set of related supervised learning methods used for classification. A support vector machine constructs a hyper plane or set of hyper planes in a high or infinite dimensional space, which can be used for classification, regression. Intuitively, a good separation is achieved by the hyper plane that has the largest distance to the nearest training data points of any class (so called functional margin), in general, the larger the margin the lower the generalization error of the classifier. Below, Table 1, Table 2 and Table3 illustrate the results of classification accuracy when work with SIFT, HOG, fusion HOG and SIFT in detail.

Table 1: Accuracy for SIFT with different clusters sizes

Cluster	Accuracy
100	79.67%
150	89.67%
200	88.33%

Table 2: Accuracy for HOG with different image sizes

Features	Accuracy
64*128	51.33%
128*128	88.33%

Table 3: Accuracy for fusion HOG and SIFT

Cluster+ Features	Accuracy
HOG (64*128) +sift(c150)	90.33%
HOG (128*128) +sift(c150)	90%

4. RESULTANTS AND DISCUSSION

The proposed method is evaluated in the presence of a real database of panoramic X-rays collected from many X-ray centers with 1000 images, 70% (700) of these images were used for training and 30% (300) for testing.

The results of the experiments were applied as follow:

When the experiment was conducted with SFT feature extraction and in different numbers of the clusters were respectively 100,150,200 was the highest classification accuracy was when the number of clusters at the Cluster 150 and the result equal 89.67%.

When experimenting with the HOG descriptor and with a different number of features ordered respectively **64 × 128** and **128 × 128** was the highest classification accuracy at the **128 × 128** and the result equal 80.33%.

When experimenting with fusion HOG and SIFT and with a different number of features and clusters, the highest classification accuracy was at the Hog **64 × 128** + SIFT (cluster=150) and the result equal 90.33%. These experiments were performed using MATLAB-R2015a and C++ with OpenCV 3.4 environment.

5. CONCLUSION

Dental panoramic x-ray images show complex nature with respect to distribution of pixel intensities. This paper presents a new approach to detect dental caries. The selection of feature plays a big role in any classification. Uses SIFT, HOG and fusion HOG and SIFT as feature detectors and descriptors then find the classification accuracy. Classify into presence or absence of caries. The classification is made by support vector machines. This yield a binary classification which group the given image set into caries (abnormal) image or healthful (normal) image. The proposed classification algorithm accounted for 90.33% of accuracy in fusion HOG and SIFT. Hence to improve the accuracy large dataset are used to train or try to experiment other feature detector or descriptor which constitute the future scope of this proposed work.

REFERENCES

- Mohanraj, M., Prabhu, V. R., & Senthil, R. (2016). Diagnostic methods for early detection of dental caries-A review. *International Journal of Pedodontic Rehabilitation*, 1(1), 29.
- Silva, G., Oliveira, L., & Python, M. (2018). Automatic segmenting teeth in X-ray images: Trends, a novel data set, benchmarking and future perspectives. *Expert Systems with Applications*, 107, 15–31. <https://doi.org/10.1016/j.eswa.2018.04.001>.
- Amer, Y. Y., & Aqel, M. J. (2015). An Efficient Segmentation Algorithm for Panoramic Dental Images. *Procedia Computer Science*, 65, 718–725. <https://doi.org/10.1016/j.procs.2015.09.016>
- Wang, C.-W., Huang, C.-T., Lee, J.-H., Li, C.-H., Chang, S.-W., Siao, M.-J., ... Lindner, C. (2016). A benchmark for comparison of dental radiography analysis algorithms. *Medical Image Analysis*, 31, 63–76. <https://doi.org/10.1016/j.media.2016.02.004>
- Oliveira, J., & Proença, H. (2011). Caries Detection in Panoramic Dental X-ray Images. In J. M. R. S. Tavares & R. M. N. Jorge (Eds.), *Computational Vision and Medical Image Processing: Recent Trends* (pp. 175–190). Dordrecht: Springer Netherlands. https://doi.org/10.1007/978-94-007-0011-6_10
- Fejerskov, O., & Kidd, E. (2009). *Dental Caries: The Disease and Its Clinical Management*. John Wiley & Sons.
- Shivpuje, B. V., & Sable, D. G. S. (2016). A Review on Digital Dental Radiographic Images for Disease Identification and Classification, 6(7), 5.
- Lee, R. C., Staninec, M., Le, O., & Fried, D. (2016). Infrared Methods for Assessment of the Activity of Natural Enamel Caries Lesions. *IEEE Journal of Selected Topics in Quantum Electronics*, 22, 102–110. <https://doi.org/10.1109/jstqe.2016.2542481>
- Ayub, S., Student, P. G., & Student, P. G. (2007). Biological Effects of X-rays on X-ray Technicians, 5(10), 5.
- Bhan, A., Vyas, G., Mishra, S., & Pandey, P. (2016). Detection and Grading Severity of Caries in Dental X-ray Images. In 2016 International Conference on Micro-Electronics and Telecommunication Engineering (ICMETE) (pp. 375–378). GHAZIABAD, India: IEEE. <https://doi.org/10.1109/ICMETE.2016.128>
- Gonsalves, P. P. (n.d.). Diagnosis of Dental Cavities using Image Processing. *International Journal of Computer Applications*, 180, 5.
- Abualigah, L. M. Q. (2019). *Feature selection and enhanced krill herd algorithm for text document clustering*. Berlin: Springer.
- Razali, M. R. M., Ahmad, N. S., Hassan, R., Zaki, Z. M., & Ismail, W. (2014). Sobel and Canny Edges Segmentations for the Dental Age Assessment. In *2014 International Conference on Computer Assisted System in Health* (pp. 62–66). Kuala Lumpur, Malaysia: IEEE. <https://doi.org/10.1109/CASH.2014.10>
- Lakhani, K., Minocha, B., & Gugnani, N. (2016). Analyzing edge detection techniques for feature extraction in dental radiographs. *Perspectives in*

- Science*, 8, 395–398.
<https://doi.org/10.1016/j.pisc.2016.04.087>
15. ALbahbah, A. A., El-Bakry, H. M., & Abd-Elgahany, S. (2016). A New Optimized Approach for Detection of Caries in Panoramic Images. *International Journal of Computer Engineering and Information Technology*, 8(9), 166.
 16. Kuang, W., & Ye, W. (2008). A Kernel-Modified SVM Based Computer-Aided Diagnosis System in Initial Caries. In *2008 Second International Symposium on Intelligent Information Technology Application (IITA)*(Vol. 03, pp. 207–211).
<https://doi.org/10.1109/IITA.2008.206>
 17. Bansal, S. (n.d.). CS676: Group 9 Dental X Ray Segmentation and Tooth Classification, 4.
 18. Olejniczak, M., & Kraft, M. (2017). Taming the HoG: The Influence of Classifier Choice on Histogram of Oriented Gradients Person Detector Performance. In L. Rutkowski, M.
https://doi.org/10.1007/978-3-319-59063-9_49
 19. Chen, Y., & Shang, L. (2016). Improved SIFT image registration algorithm on characteristic statistical distributions and consistency constraint. *Optik*, 127(2), 900–911.
<https://doi.org/10.1016/j.ijleo.2015.10.145>
 20. Liu, Z., Liu, W., & Yuan, J. (2016). CS229 Final Report: Bismuth Vanadate (111) Facet Detection, 6.
 21. Kantardzic, M. (2011). *Data Mining: Concepts, Models, Methods, and Algorithms*. John Wiley & Sons.
<https://doi.org/10.1002/9781118029145>